

A Study of Soleus Muscle – Clinical and Embryological consideration

Shinde Amol A*, Patel Dinesh K and Bharambe Vaishaly K

Dr. D. Y. Patil Medical college, Pimpri, Pune, Maharashtra, India

*Correspondence Info:

Dr. Shinde Amol A,
Assistant Professor,
Dr. D.Y. Patil Medical College,
Pimpri, Pune, Maharashtra, India
E-mail: amol9267@gmail.com

Abstract

Objectives: Soleus is a multipennate muscle of back of leg taking origin from tibia and fibula as a single belly. It inserts on calcaneum as Achilles tendon and acts as a plantar flexor of foot. Aim of the study was to find variations in origin, insertion, nerve supply and number of muscle bellies of soleus.

Material and Methods: 50 lower limbs were meticulously dissected to observe variations in soleus muscle.

Results: 8 % limbs showed accessory head of soleus. 4 heads, 3 heads and 2 heads of soleus were observed. Variations of tibial nerve while supplying the accessory heads were noted.

Conclusion: Symptomatic cases with accessory soleus have presented in athletes. Due to sedentary lifestyle most of the cases are passing unnoticed. Cases of neurovascular entrapment and clubfoot deformity have required surgical intervention. Knowledge of variations of soleus will be of prime importance during diagnostic procedures.

Keywords: Accessory head of soleus, Tibial nerve entrapment, Achilles tendon, Supernumerary head of soleus and Soleus secundus.

1. Introduction

Soleus is a broad, flat muscle located in front of Gastrocnemius muscle in the leg. A single muscle belly is seen taking origin from back of tibia above the soleal line and across back of head of fibula. The tendons of Soleus and gastrocnemius together form the Achilles tendon (Tendo calcaneum, Tendo Achilles) which inserts on the back of Calcaneum bone [1].

The name soleus is derived from a latin word 'Solea' meaning sandal. It is a multipennate muscle with more composition of slow acting muscle fibers. Soleus acts as a powerful plantar flexor of foot. While walking it helps to overcome the initial inertia of the body. In standing position it helps in pumping venous blood back to the heart from the periphery so is called Peripheral heart, Calf pump, Sural pump and Tricipital pump. [2]

Additional heads of soleus have been documented in literature. Gruvelhier first named it "supernumerary soleus" in 1843, and in 1871 Pye Smith used the term "soleus secundus". [3]

2. Materials and methods

50 limbs from 25 formalin embalmed cadavers were meticulously dissected. Variations of soleus muscle like

number of heads, nerve supply and insertion were observed. 23 male and 2 female cadavers were dissected.

The length of the tendon was measured from musculotendinous junction of soleus muscle to the most proximal point of insertion site of the tendon on calcaneum using vernier caliper.

3. Observations and results

Accessory bellies of soleus were seen in 4 limbs (8%) during meticulous dissection of 50 limbs of 25 formalin embalmed cadavers. (Figure 1 & 2) Four bellies of soleus were seen in a left side limb. 3 bellies of soleus were seen in one right side limb. The same limb also showed a accessory head of Gastrocnemius. One cadaver showed 2 bellies of soleus bilaterally. All the variations were seen in male cadavers.


All the accessory heads were joining to form Achilles tendon and got inserted at the posterior end of Calcaneum. Length of muscle bellies and length of Achilles tendon is tabulated in table 1.

One cadaver which was showing bilateral variation had the tibial nerve branching above the plantaris muscle to give two branches for soleus. Two limbs showed tibial nerve branching at level of plantaris with nerve on either side of plantaris tendon (Figure 2).

Table 1: Length of muscle bellies and length of Achilles tendon

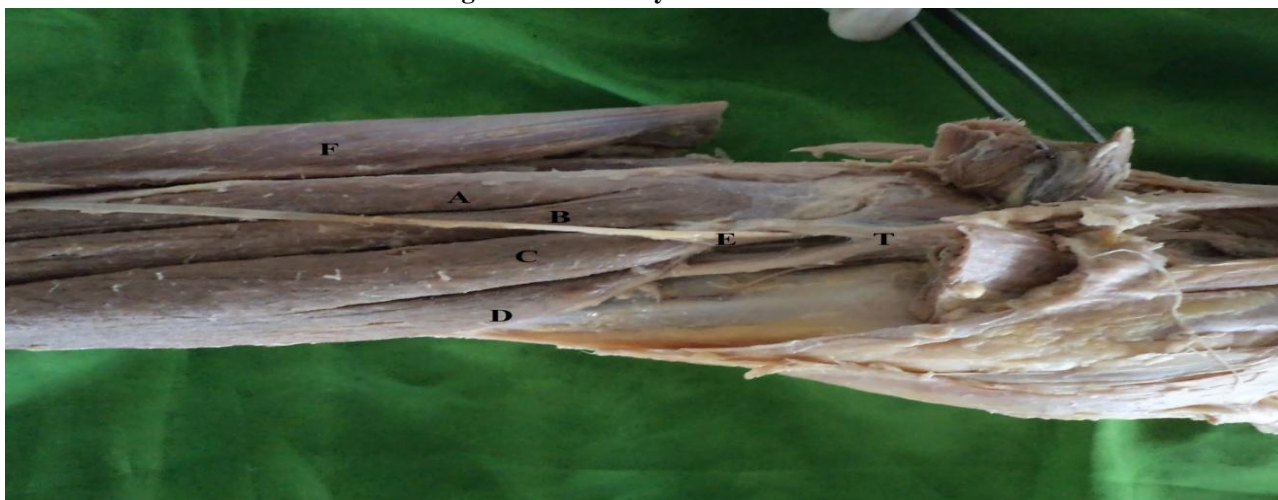
Sr. No	Side	Number of bellies of Soleus	Muscle length (cm)	Tendon length (cm)
1	Left	4	21.6	6.9
			26.9	
			27.4	
			24.6	
2	Right	3	27.6	7.2
			24.1	
			25.9	
3	Right	2	29.5	12.5
			27.2	
4	Left	2	29.3	12.8
			27.8	

Figure 1: Accessory bellies of soleus



A and B– Fibular heads of Soleus, C and D – Tibial Heads of Soleus, E – Plantaris, F- Gastrocnemius, G – Achilles tendon, T – Tibial Nerve

Figure 2: Accessory bellies of soleus



A and B– Fibular heads of Soleus, C and D – Tibial Heads of Soleus, E – Plantaris, F- Gastrocnemius, G – Achilles tendon, T – Tibial Nerve

3.1 Embryological consideration

Early splitting of a single anlage of the soleus muscle is the embryological reason for this variant anatomy.[3]

During embryogenesis soleus muscle initially separates into two parts. Both parts fuse to form a single muscle. Early splitting can cause development of an extra fasciculus or even a supernumerary muscle. Non fusion of these bellies will result in formation of two or more

supernumerary muscles. Each additional head will have separate nerve and blood supply.[4] The tibial nerve which supplies soleus muscle branches to supply all the heads.

4. Discussion

The soleus muscle lies in the postero medial part of the leg, under the gastrocnemius muscle. Originating from tibia and fibula and forms the aponeurosis which inserts into

calcaneum. The incidence of accessory soleus ranges from 0.5% to 6% of the population.[5] Present study reports incidence of 8%. A higher incidence of 10% and 11.6% have been reported by Koubalchouck[6] and Del Nero[4] respectively.

Trivedi *et al* reported a case of accessory head of soleus muscle, presenting as a tumefaction in the posteromedial region of the ankle. The author stated that athletes with symptoms precipitated after increased physical activity comprised the maximum of case presented. The incidence of the accessory soleus can be more as most of the cases may go unnoticed due to increase in the sedentary lifestyle. Symptomatic cases of compression symptoms required surgical intervention.[7]

Kishta *et al* reported 10 cases of clubfeet which presented with accessory soleus muscle. 4 patients presented this variation bilaterally. So it is very important to check for accessory soleus muscle, in children with clubfeet. Release of accessory muscle is required for full correction. Ignoring this variation may result in persistent hind foot deformity.[8]

Rossi *et al* reported a case of a 18yr old soccer player with a symptomatic accessory soleus. The massive accessory soleus (17cm length-5cm breadth -4cm thickness) was excised and the boy returned to soccer training after 3 months. The authors state that accessory soleus is found in 0.7 to 5.5% population. Treatment options like conservative treatment, excision, fasciotomy, release and closure of blood supply are used. Fasciotomy and excision have given good results in athletes.[9]

Sawant S.P.[10] mention a classification of accessory heads of soleus. 5 types of accessory heads were described as per their insertion. First type was muscle inserting in Achilles tendon. Second type had muscle inserting on upper end of calcaneum. A third type had insertion of a tendon at the upper end of calcaneum. Fourth type showed the accessory muscle inserting on medial surface of calcaneum and a fifth type showing a tendon inserting on the medial side of calcaneum.

Fatos Belgin Yildirim *et al* report a case of bilateral gastrocnemius tertius muscle and a unilateral accessory soleus muscle. Accessory head of soleus was taking origin from posteromedial aspect and soleal line of tibia and was inserting separately on the medial surface of calcaneum. Author states that accessory soleus have been reported clinically from age of 3 months to 66 years but the average age is 21 years.[11]

Joshi *et al* reported 10% incidence of accessory soleus muscles. They mention accessory head inserting separately on calcaneum. Length of the additional tendon ranging from 3.5 to 4.5 cm [12]

In a study of accessory soleus, Singh *et al* [13] report length of Achilles tendon to be 7 cm while Gosavi *et al* [14] mention 10 cm and 12 cm long Achilles tendon in a case of bilateral accessory soleus muscle. These findings coincide

with our study showing length of tendon ranging from 6.9 to 12.8 cm.

Christodoulou *et al* [3] consider accessory soleus as an anomalous muscle mimicking soft tissue tumours. This condition is also confused with ganglion, lipoma, haemangioma, synovioma and sarcoma. Pain and swelling on high intensity physical activity in athletes are noted symptoms. Onset of symptoms is delayed till adolescence mostly due to increased muscle mass and sports activity. Around 25% cases are asymptomatic. Fasciotomy or excision is the treatment of choice in symptomatic cases.

In a MR neurography assisted study, Chhabra *et al* [15] report role of accessory soleus muscle in tibial nerve entrapment syndromes. Soleal fibromuscular sling compressing the tibial nerve was seen on MRN in cases reporting of parasthesia at calf region.

Reddy and McCollom [16] reported a case of a cyclist with accessory soleus. He presented with activity related parasthesia of leg suggesting tibial nerve compression. Treatment options for mentioned were conservative management, excision of accessory muscle and fasciotomy.

5. Conclusion

Variations in number of muscle bellies and nerve supply of soleus muscle are well documented. Accessory soleus has been presenting as a symptomatic case in athletes. Due to sedentary lifestyle most of the cases are passing unnoticed. Neurovascular entrapments have required surgical interventions like excision and fasciotomy. Pediatric cases of clubfoot deformity require complete release of accessory soleus, failing which the child may present with persistent hindfoot deformity.

Our study showed variant positions of branching of tibial nerve with relation to plantaris tendon while supplying accessory heads of soleus. Knowledge of these variations of soleus will be of prime importance during diagnostic procedures.

References

- [1] Standring S, editor, Johnson D, section editor. Gray's Anatomy - The Anatomical Basis of Clinical Practice. 40th ed. London: Churchill Livingstone Elsevier; 2008; 6: 825-26.
- [2] Soleus muscle - Wikipedia, the free encyclopedia. https://en.wikipedia.org/wiki/Soleus_muscle
- [3] Christodoulou A, Terzidis I, Natzsis K, Gigis I, Pournaras J. Soleus accessorius, an anomalous muscle in a young athlete: case report and analysis of the literature. *Br J Sports Med* 2004; 38:e38. doi:[10.1136/bjism.2004.012021](https://doi.org/10.1136/bjism.2004.012021)
- [4] Del Nero FB, Ruiz CR, Junior RA. The presence of accessory soleus muscle in humans. *Einstein*. 2012; 10(1): 79-81.

- [5] Francisco J. Rubioa, Luis Francoa, Manuel J. Monterob, Paola Ugartea and Alfredo Valeroa Accessory soleus muscle in an athlete. Presentation of a case and a literature review. *Apunts Med Esport*. 2015; 50(186):79-82.
- [6] Kouvalchouk JF and Lecocq J, Parier J The accessory soleus muscle: a report of 21 cases and a review of the literature. *Rev Chir Orthop Reparatrice Appar Mot*. 2005; 91:232-8.
- [7] Trivedi S, Athavale SA, Kotgiriwar S, Sinha TP, Siddiqui AU. Accessory soleus muscle and its clinical significance. *Int J of Biomed & Adv Res*. 2013 Dec; 4(12): 950-952. doi: <http://dx.doi.org/10.7439/ijbar.v4i12.592>
- [8] Kishta WE, Mansour EH, Ibrahim MM. The accessory soleus muscle as a cause of persistent equinus in clubfeet treated by the Ponseti method: A report of 16 cases. *Acta Orthop Belg*. 2010 Oct; 76(5): 658-62.
- [9] Rossi R, Bonasia DE, Tron A, Ferro A, Castoldi F. Accessory soleus in the athletes: literature review and case report of a massive muscle in a soccer player. *Knee Surg Sports Traumatol Arthrosc*. 2009 Aug; 17(8): 990-5.
- [10] Sawant S.P. A Case Report on Bilateral Three Separate Heads of Soleus Muscle and its Clinical Importance. *World Research Journal of Orthopedics* 2013; 1(1): 04-06.
- [11] Fatos Belgin Yildirim, Levent Sarikcioglu and Koh Nakajima. The Co-existence of the Gastrocnemius Tertius and Accessory Soleus Muscles. *J Korean Med Sci*. Oct 2011; 26(10): 1378–1381.
- [12] Joshi Sheetal B., Garude Pradnya V., Kale Amit, Bahetee B. H., Mandke Nutan D., Chandanwale Ajay. Study of Accessory Soleus - An Anatomical and Clinical Insight. *Journal of Evolution of Medical and Dental Sciences* 2014; 3 (29): 8059-8066.
- [13] Singh, S., Suri, R.K., Mehta, V., Loh, H., Arora, J. and Rath, G. Bilateral additional bellies of soleus muscle: Anatomical and clinical insights. *International Journal of Anatomical Variations*, 2009; 2: 20–22.
- [14] Gosavi, S. R., Gajbe, U. L., Andmeshram, S. Accessory soleus muscle: a rare tissue variation with Its clinical significance. *Journal of Cell and Tissue Research* 2011; 11(1): 2541 – 2543.
- [15] Chhabra A, Williams EH, Subhawong TK, Hashemi S, Soldatos T, Wang KC, Carrino JA. MR Neurography Findings of Soleal Sling Entrapment. *AJR Am J Roentgenol* 2011 Mar; 196(3): W290-7. doi: 10.2214/AJR.10.4925.
- [16] Reddy P and McCollum GA. The accessory soleus muscle causing tibial nerve compression neuropathy: A case report. *SA Orthop. J*. 2015; 14 (4). <http://dx.doi.org/10.17159/2309-8309/2015/v14n4a8>